

## PELVISCROTAL VASOVASOSTOMY: REFINING AND TROUBLESHOOTING

OSAMA K. Z. SHAEER\* AND KAMAL Z. SHAEER

*From the Department of Andrology, Faculty of Medicine, Cairo University, Cairo, Egypt*

### ABSTRACT

**Purpose:** Obstruction of the vas deferens in the inguinal canal may occur as a sequel of inguinal surgery. The condition is occurs in 26.7% of cases following childhood herniotomy. Open surgery in the inguinal region for anastomosing the remnants of the vas is difficult and associated with high morbidity. We have previously reported an alternative based on anastomosing the pelvic vas deferens (harvested laparoscopically) to the scrotal vas deferens and bypassing the inguinal vas. This technique, termed Shaeer pelviscrotal vasovasostomy, is easier to perform with much less morbidity. In this study we present the results of performing the procedure bilaterally at the same session as well as technique troubleshooting.

**Materials and Methods:** A total of 25 patients with azoospermia due to inguinal obstruction of the vas deferens underwent unilateral (15) or bilateral (10) surgery. Patients were followed for 1 year.

**Results:** Of the 25 patients 17 (68%) had a sperm concentration of between 11.88 and 17 million per ml. Some patients who remained azoospermic underwent reoperation and the obstacles to a successful anastomosis were analyzed and resolved.

**Conclusions:** Shaeer vasovasostomy is a practical approach to inguinal obstruction of the vas deferens. It enables a reliable anastomosis, simultaneous bilateral repair and lower morbidity in terms of wound healing and hernia as well as a shorter convalescence.

**KEY WORDS:** testis, vas deferens, surgical anastomosis, vasovasostomy, hernia

Obstruction of the vas deferens in the inguinal canal is a possible sequela of inguinal surgery. It has been reported in up to 26.7% of cases of childhood herniotomy.<sup>1</sup> The mechanism of injury can be cutting, crushing or over stretching. Adults are not immune, especially if mesh is used for hernioplasty.<sup>2</sup>

While surgical exploration of the inguinal region has been done to find the remnants of the vas deferens for approximation and anastomosis, this technique has some negative aspects. Dissection through the site of previous hernia repair is hindered by fibrosis and mesh, if present. If the condition is bilateral, management of the 2 sides can be difficult at 1 session. The healing power of inguinal incisions placed through old scars is relatively poor, increasing morbidity. More important is the state of the vas deferens remnants, which may not be found. If they are found, they may be devitalized or too separated, making approximation difficult and causing the anastomosis to be under tension.

In 2003 we proposed an alternative, that is pelviscrotal vasovasostomy (PSVV).<sup>3</sup> This is a technique by which the pelvic vas deferens is mobilized, detached from the internal ring, medialized and pulled out of the pelvis through the external inguinal ring. It is then anastomosed to the scrotal vas, bypassing the inguinal vas. We first reported PSVV in 2003 in a case report<sup>3</sup> and then in 2004 as a series of 15 cases performed unilaterally.<sup>4</sup> A similar technique was described in 2004 by Kim et al in a case report.<sup>5</sup> In this study we present cumulative 4-year also experience with the technique and with 1-session bilateral repair. In addition, we identified and resolved obstacles hindering the success rate.

### MATERIALS AND METHODS

We operated in 60 men with obstructive azoospermia who had undergone bilateral hernia repair. Of the 60 cases 25 had

Submitted for publication January 1, 2005.

\* Correspondence: 21 Gaber Ibn Hayan St., Dokki, Giza, Egypt, 12311 (telephone: 002023359047–002023374360; FAX: 002027605181).

inguinal obstruction, as proven by intraoperative vasography. PSVV was performed unilaterally in 15 patients and bilaterally in 10.

The procedure was performed with the patient under general anesthesia. The 2 testicles were delivered through a midline scrotal incision. The 2 vasa were cannulated cranial and vasography was performed. The vasa were bent at a 90-degree angle and cannulated at the point of maximum curvature using a small gauge butterfly cannula. Contrast medium was subsequently injected. This was not performed on the side of an atrophied testis, which was present in 8 cases. Inguinal obstruction detected in 25 cases was unilateral in 15 and bilateral in 10 (fig. 1).

Laparoscopic access was established. Pneumoperitoneum was induced. Three ports were inserted, including a 10 mm port inserted periumbilically for visualization and 2, 5 mm working ports inserted on either side midway between the umbilicus and anterior superior iliac spine for instruments. The head of the operating table was tilted down.

The vas was identified beneath the peritoneum of the posterior abdominal wall. The overlying peritoneum was incised and the vas was picked up and freed from the surrounding tissues (fig. 2). It was then clipped and cut at the internal inguinal ring. The cut vas was picked up by a grasper inserted through the external inguinal ring via a 5 mm port. The grasper holding the vas was pulled out together with its port in the same maneuver, extruding the pelvic vas to the surface (fig. 3).

The stump of the vas was trimmed, so that it would recede relative to the occluded end of the vassal artery. This may help provide vascularity to the anastomosis. It also eliminates the part of the vas that was crushed by the grasper.

The scrotal vas was exposed through the suprapubic incision for the latter port and cut where it dips into the external ring. The vas was cannulated caudal and gently irrigated with sperm medium. The medium was aspirated and exam-

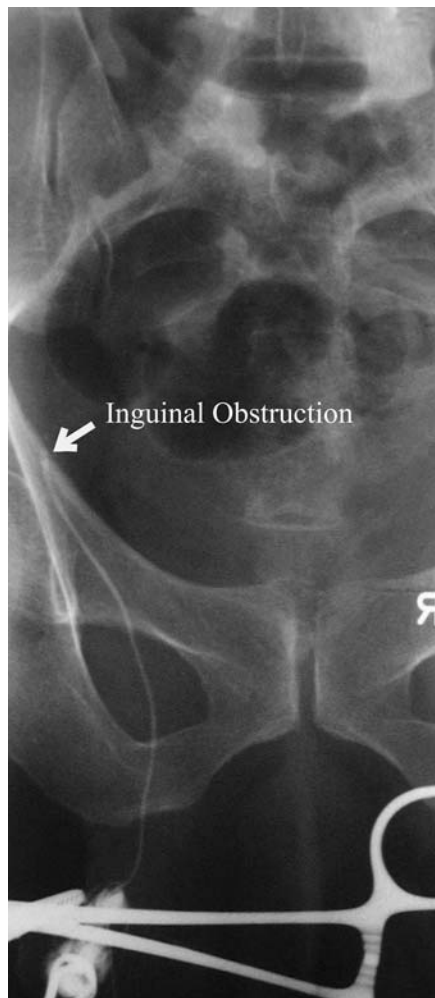

FIG. 1. Vasography shows inguinal obstruction (arrow)

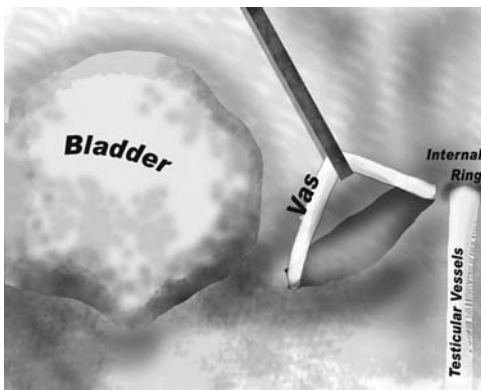


FIG. 2. Vas deferens dissected off of posterior abdominal wall

ined for sperm. The aspirated fluid was relatively turbid and positive for sperm on each side in all cases. The stump was then anastomosed to the pelvic vas. End-to-end anastomosis was performed under optical magnification in a 2 layer fashion in 12 cases and in 1 layer in 13. A microvascular vessel dilator was used to dilate each stump of the vas to facilitate performing the anastomosis. Two-layer vasovasostomy was achieved by mucosal anastomosis using 6, 10-zero nylon sutures and seromuscular anastomosis was performed using 6, 9-zero nylon sutures. For 1 layer vasovasostomy 6, 8-zero nylon sutures were placed that spanned the whole thickness of the vas with the knots on the outer surface.

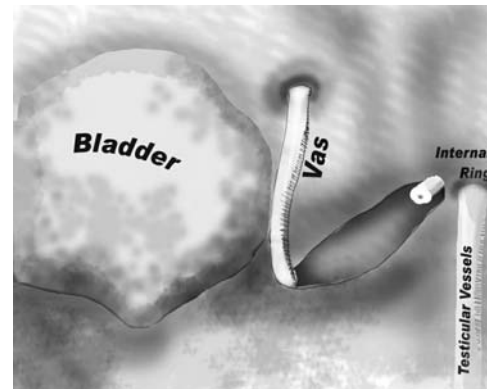


FIG. 3. Vas deferens extruded through external inguinal ring

The maneuver for picking up the pelvic vas with a grasper through a 5 mm port was modified based on our long-term experience with the technique. Four patients who were still azoospermic after the procedure underwent scrotal exploration for possible caudal obstruction requiring epididymovasostomy. Intraoperative vasography showed obstruction at the level of the external ring rather than at the site of anastomosis. The anesthesiologist was asked to induce total muscle relaxation and vasography was repeated. This resulted in the free passage of dye up to the bladder. We concluded that the aperture in the abdominal wall may be too small to allow unhindered passage of the vas, especially in men with stronger abdominal muscles. We modified the technique accordingly.

We started by using a 10 rather than a 5 mm port for retrieving the vas through the external ring. Eventually we came to create an indirect passage rather than a direct one, that is a miniature inguinal canal. We made a short superficial incision in the rectus abdominis muscle or conjoint tendon and then used a right-angle instrument, of which the blades were opened widely in the horizontal plane to create a space between the muscle fibers in the muscle bulk. It was then rotated, so that it dipped through the abdominal wall and into the pelvis to pick up the vas. We applied cutting diathermy current to the instrument to facilitate entry and then coagulating current to the instrument as it resided in the passage to decrease the healing power of the boundaries of this passage.

In bilateral cases a midline horizontal penopubic incision was made to retrieve the vasa through the external inguinal rings, avoiding the scars of hernia repair. In unilateral cases the incision was made over the corresponding external ring.

Average skin-to-skin laparoscopy time was 25 minutes in unilateral cases and 35 minutes in bilateral cases. Patients were discharged home the second day following surgery. Return to work was achieved within 4 days.

## RESULTS

Patients were followed by semen analysis every third month for 1 year. By the end of 1 year 9 of the 15 unilateral cases yielded sperm with an average concentration  $\pm$  SD of 11.88 million per ml  $\pm$  4.55. One of the 9 patients had a relapse of azoospermia that was refractory to medical treatment due to severe pyospermia while not attending followup sessions. Eight of the 10 bilateral cases showed an average sperm concentration of  $17 \pm 3.5$  million per ml. Three patients in this group achieved conception naturally. In all cases yielding sperm average hour 1 motility was 35% but mostly sluggish. This improved with time and medical treatment.

Six of the 8 men with persistent azoospermia after the procedure attended followup sessions and 2 dropped out. The

6 patients with azoospermia underwent scrotal exploration. The vas was tested for patency, cranially by vasography and caudally by the injection of sperm medium, followed by aspiration and testing for sperm. In 4 patients the vas was occluded at its exit through the external inguinal ring, as previously described. The exit was dilated. In 2 patients cranial patency was confirmed but caudal patency was not. Epididymovasostomy was performed. Five patients yielded sperm with an average concentration of  $8 \pm 3.2$  million per ml.

The patency rate for unilateral and bilateral correction was 60% and 80%, respectively, and the overall patency rate was 68%. This increased after reoperation to an overall patency rate of 88%.

#### DISCUSSION

PSVV provides some advantages over open inguinal vasovasostomy. Three short incisions, each 1 cm, are placed in the nonscarred abdomen, in contrast to 2 long inguinal incisions placed through old scars. Dissection is easy and linear, in contrast to the open procedure, in which searching for remnants of the vas is done through the fibrosed site of hernia repair and through a mesh. There is no risk of hernia recurrence, in contrast to the open procedure. The remnants of the vas are more healthy and under no tension, unlike in the open procedure. Hospital stay and convalescence are much shorter, and return to work is earlier.

With cumulative experience with PSVV we learned how to create a new exit for the vas deferens that is wide enough to

allow free passage of the patent vas but not to allow prolapse of a hernia. This step is crucial for seminal tract patency. We also learned that there is a possibility that the patient will require epididymovasostomy with PSVV, especially if there was a prior trial at restoring patency.

Management of the 2 sides at the same session is easy and cost-effective, and it provides a higher fertility potential. In our experience 1 layer anastomosis provided the same results as 2 later anastomosis and was less time-consuming, allowing bilateral repair and even epididymovasostomy. In conclusion, PSVV is a practical approach to inguinal obstruction of the vas deferens, providing a reliable anastomosis and simultaneous bilateral repair with lower morbidity in terms of wound healing and hernia occurrence as well as a shorter convalescence.

#### REFERENCES

1. Matsuda, T.: Diagnosis and treatment of post-herniorrhaphy vas deferens obstruction. *Int J Urol*, suppl., 7: S35, 2000
2. Hendry, W. F., Levison, D. A., Parkinson, M. C., Parslow, J. M. and Royle, M. G.: Testicular obstruction: clinicopathological studies. *Ann R Coll Surg Engl*, 72: 396, 1990
3. Shaeer, O. K. Z., Sadat, A. and Shaeer, K. Z.: Laparoscopy and microsurgery aided pelvi-scrotal vasovasostomy "Shaeer's vaso-vasostomy". *Egypt J Androl Reprod*, 17: 37, 2003
4. Shaeer, O. K. and Shaeer, K. Z.: Laparoscopy-assisted pelvi-scrotal vasovasostomy. *Andrologia*, 36: 311, 2004
5. Kim, A., Shin, D., Martin, T. V. and Honig, S. C.: Laparoscopic mobilization of the retroperitoneal vas deferens for microscopic inguinal vasovasostomy. *J Urol*, 172: 1948, 2004